

# Insights into Lichen Planus Pigmentosus Inversus using Minimally Invasive Dermal Patch and Whole Transcriptome Analysis

**Keywords:** Lichen Planus Pigmentosus; Keratin; Minimally Invasive Dermal Patch

## Abstract

Lichen Planus Pigmentosus inversus (LPPi) is a rare interface and lichenoid dermatitis (ILD) and supposed variant of lichen planus (LP) that presents as well-demarcated brown to grey macules in flexural and intertriginous areas. LPPi is deemed 'inversus' because its anatomical distribution in skin folds is opposite that seen in lichen planus pigmentosus (LPP) whose pigmented lesions arise on sun-exposed skin. Biopsy is required for the clinical diagnosis of all ILDs. Though multiple clinically-oriented studies have reported differences between LPP, LPPi, and LP, few molecular studies have been performed. In this case study, 3 patients, 2 with LPPi and one with LP, provided samples using minimally invasive whole transcriptome analysis using a dermal biomarker patch. This study confirms the involvement of interferon signaling and T-cell activation in LPPi and suggests an expression profile distinct from LP. Specific genes significantly upregulated in LPPi vs LP include an intergenic splice variant of the primary pigmentation determining receptor in humans and dysregulation of genes essential for ceramide synthesis and construction of the cornified envelope. This work expands upon our knowledge of the pathogenesis of LPPi vs LP, and supports the potential use of this technology in the diagnostic clinical setting to mitigate the need for invasive procedures.

## Introduction

Lichen Planus Pigmentosus Inversus (LPPi) is a rare and poorly understood variant of Lichen Planus (LP) characterized by hyperpigmented well-demarcated lesions that are limited to intertriginous and flexural areas of the body. Unlike LP, lesions of LPPi are less symptomatic, with only occasional pruritus. Originally described by Pock in a case series from the Czech Republic, LPPi has now been reported in scores of patients around the world with a variety of skin phototypes [1-3]. It was initially described "inversus" because the anatomical distribution was opposite that of traditional lichen planus pigmentosus (LPP) which is found on sun-exposed skin of the face, neck, and upper extremities in darker skin phototype populations [4]. Classically, LPP is also symmetrical and diffuse with poorly defined borders. This entire class of skin diseases is grouped together based upon a shared histopathologic pattern first described in LP. This "lichenoid tissue reaction" [(LTR) - better described as an interface and lichenoid dermatitis (ILD)] includes damage to basal layer keratinocytes accompanied by band-like lymphohistiocytic infiltrate along the dermoepidermal junction [5,6]. LPP and LPPi's histology differs from LP in a few important ways: a) the additional finding of abundant melanin incontinence in the superficial dermis manifested by the presence of melanophages, which results in the hyperpigmentation seen clinically, b) a relatively atrophic epidermis

(as compared to the acanthosis seen in LP) accompanied by c) orthokeratosis of the cornified layer of cells.

Powerful gene expression tools deployed on ILDs (LP as well as lupus erythematosus) identified the type I immune response (IFN-gamma and TNF-alpha signaling) as the fundamental components inducing keratinocyte necroptosis in this class of skin disease [7]. LP specifically has shown elevated expression of IFN-gamma inducible cytokine CXCL9 as a marker distinguishing it from other common skin conditions, while research on the oral version of LP displayed marked elevation of CXCR3 and its ligands in secretory granules as critical to the continuing autologous recruitment of cytotoxic CD8<sup>+</sup> T cells [8,9]. Recently, research by Kumuran and colleagues into the pathogenesis of LPP found significantly reduced expression of Th17 related genes, IFN-gamma, and Foxp3 in LPP vs LP calling into question the longstanding shared taxonomy of these two diseases [10].

There is a decades old debate regarding the classification and nomenclature of lichenoid tissue reactions (LeBoit 1993), the pigmented skin conditions noted above, and other melanin-rich inflammatory processes (*i.e.* ashy dermatosis, erythema dyschromicum perstans) which are more commonly described internationally and whose aesthetics differ from person to person [11-14]. Subtyping and characterizing uncommon skin disorders is integral to science and increasingly powerful given technology's rapid advances [15-17]. The goal of this study is to use whole transcriptome profiling with dermal biomarker patch (DBP) [18] to investigate the pathogenesis of LPPi vs LP. *Via* this novel biomarker extraction tool, differential gene expression of LPPi vs LP can be performed to identify upregulated and downregulated genes as compared with non-lesional skin (NLS) and the expression of inflammatory markers and other important genes can be judged in LPPi vs LP. Finally, gene expression



## Journal of Clinical & Investigative Dermatology

Dickman J<sup>1\*</sup>, Howell M<sup>1\*</sup>, Hoopes R<sup>1</sup>, Wang Y<sup>2</sup>, Dickerson TJ<sup>2</sup>, Bottomley M<sup>3</sup>, Shamma HN<sup>4,5</sup>, Rapp CM<sup>1</sup>, Turner MJ<sup>6,7</sup>, Rohan CA<sup>1,4</sup> and Travers JF<sup>1,4,8</sup>

<sup>1</sup>Departments of Pharmacology & Toxicology, Wright State University, USA

<sup>2</sup>Mindera Corporation, San Diego, California

<sup>3</sup>Departments of Mathematics & Statistics, Wright State University, USA

<sup>4</sup>Department of Dermatology, Wright State University, USA

<sup>5</sup>American Dermatopathology, LLC, Centerville, Ohio, USA

<sup>6</sup>Department of Dermatology, Indiana University School of Medicine, USA

<sup>7</sup>Roudebush Veterans Administration Medical Center, USA

<sup>8</sup>Dayton Veterans Administration Medical Center, USA

### \*Address for Correspondence

Travers JF, Departments of Pharmacology & Toxicology, Wright State University, Dayton, Ohio, USA; Email: jeffrey.travers@wright.edu

**Submission:** 01 March, 2022

**Accepted:** 05 April, 2022

**Published:** 05 April, 2022

**Copyright:** © 2022 Dickman J, et al. This is an open access article distributed under the Creative Commons Attribution License, which permits unrestricted use, distribution, and reproduction in any medium, provided the original work is properly cited.

profiles of LPPi and LP can be used for enrichment analysis to unveil the biological and molecular pathways overrepresented in each disease and perhaps shed light on otherwise opaque pathologies.

## Material Methods

These studies were approved by the Wright State University Institutional Review Board and informed consent was obtained from the subjects before initiating the protocol. The three patients were enrolled into a study testing the ability of the minimally invasive Minderadermal biomarker patches (DBP) for sample extraction followed by next generation sequencing was performed as per the manufacturer's guidelines [18]. The patches were placed onto normal orlesional skin via use of the provided dermal spring-loaded biomarker patch applicator (see Supplementary Figures S1-S3 depicting actual placements). The dermal patch was left on the skin for 5 minutes by a ring of medical tape. At this time, the patch was gently removed from the subject and immediately placed into storage buffer (LiCl, Triton X-100, Tris-EDTA) and stored at 4°C for less than one week before processing.

## Transcriptome Extraction/Analysis

Upon sample received, the Mindera process work-flow was as follows: (1) mRNA biomarker elution; 2) RNA Pre-amplification; 3) conversion to cDNA library; 4) DNA sequencing; 5) RNA-seq data analysis. RNA sequencing data analysis included alignment, feature counts, normalization, and differential analysis. These details are exactly as outlined in recently published manuscript [18]. The measurement of RNA expression level, log base 2 counts per million (logCPM), and data normalization were performed using edgeR package from Bioconductor. Differential analysis was performed using LIMMA package from Bioconductor, in which log base 2 fold change (logFC) and moderated t-test data were calculated for statistical significance.

Finally, relative gene expression data was used to generate a ranked gene list using fold change between LS and NLS, and LP vs LPPi expression levels. This ranked gene list underwent GSEA pathway enrichment analysis using MSigDB Canonical Pathways Database which includes Reactome, PID, Kegg, and Biocarta curated gene sets [19]. Other parameters used are included in supplemental files. R open source software for statistical computing and graphics was used for analysis and data presentation.

## Results

### Subject information

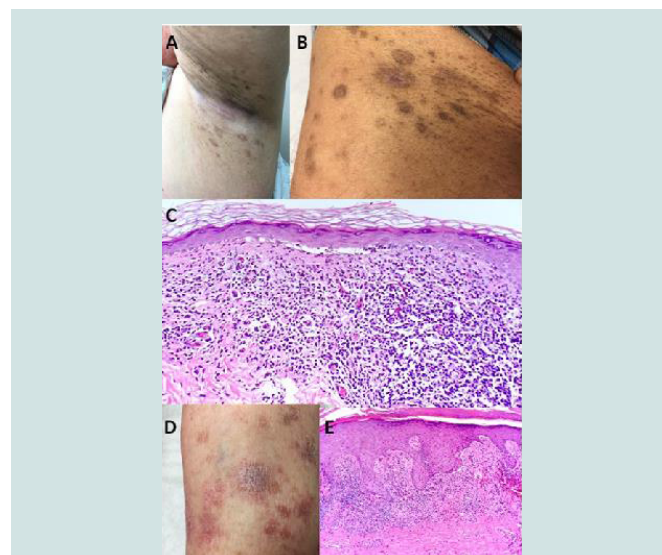
Our first LPPi patient is a 67 yearold female with Fitzpatrick type II skin with more than a year history of a minimally pruritic eruption involving her inguinal, inframammary, axillary, and lower abdominal skin with mild tenderness and dysesthesia. Medical history was significant for type 2 diabetes mellitus and mild obesity. As noted in Figure 1A, the patient exhibited brown to greyish colored macular lesions without significant scale in bilateral axillary vaults, inframammary skin, inguinal folds, and proximal medial thighs. The second patient was 40-year-old Indian Asian male with Fitzpatrick type IV skin on no medications nor supplements with a 10-month history of brown to almost black colored minimally raised oval thin plaques with minimal scale involving intertriginous groin and axillary skin (Figure 1B). Shave biopsies from the patients were very similar

and revealed focal atrophy of the epidermis with loss of rete ridges and few junctional necrotic keratinocytes. An underlying lichenoid lymphohistiocytic infiltrate with melanophages was noted (Figure 1C). Diagnoses of LPPi were determined at this time for these two patients. Neither patient had a history of bismuth use, and hepatitis B and C panels were negative. The first patient with LPPi was prescribed ketoconazole 2% cream and hydrocortisone 2.5% ointment. After several months the patient was treated with topical pimecrolimus 1% cream with some improvement. The second patient with LPPi did not desire treatment.

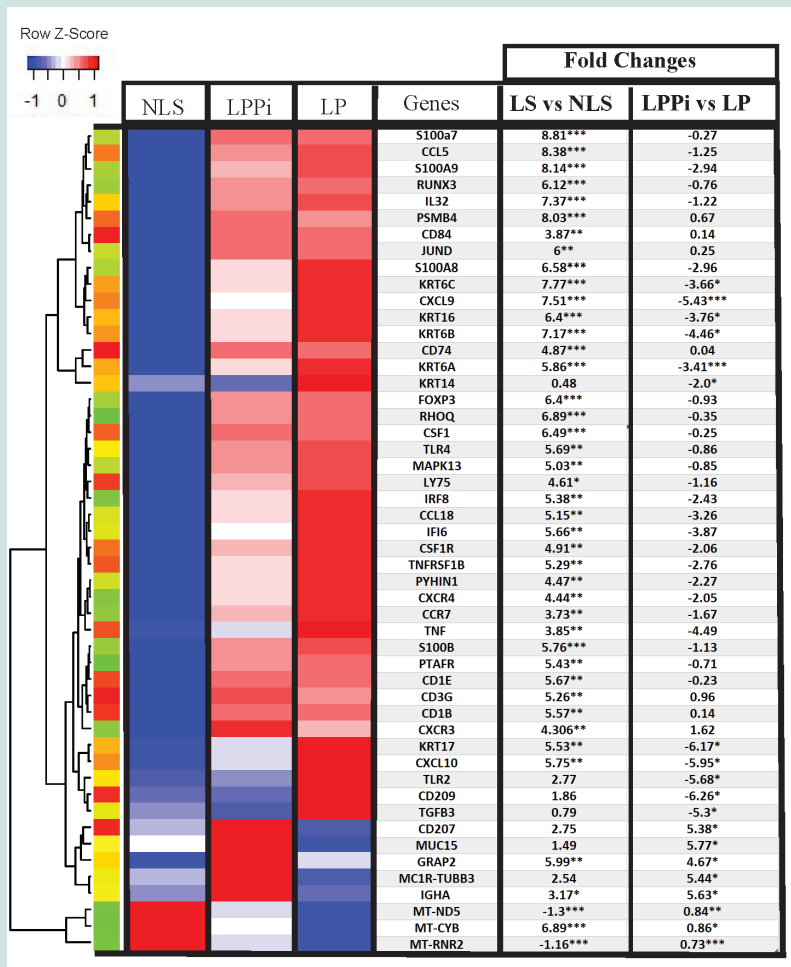
A 75-year-old female with Fitzpatrick type II skin presented with a pruritic eruption on bilateral feet and ankles for 1 month. The patient denied lesions involving her mouth and groin. The patient stated she had been treated for lichen planus 10 years prior which had resolved after two years with topical corticosteroid monotherapy. Her only medications were hydrochlorothiazide and paroxetine which were stable for the past two years. Physical exam revealed scattered erythematous and violaceous papules and plaques on the bilateral feet and ankles (Figure 1D). A 4-mm punch biopsy was taken from the patient's dorsum of her right foot. Histopathological evaluation demonstrated irregular epidermal acanthosis, wedge-shaped hypergranulosis, and intraepidermal necrotic keratinocytes. The superficial dermis was also notable for a predominately lymphohistiocytic infiltrate (Figure 1E). A diagnosis of LP was determined at this time. Hepatitis B and C panels were negative.

## Mindera Dermal Biomarker Patch Transcriptome Testing

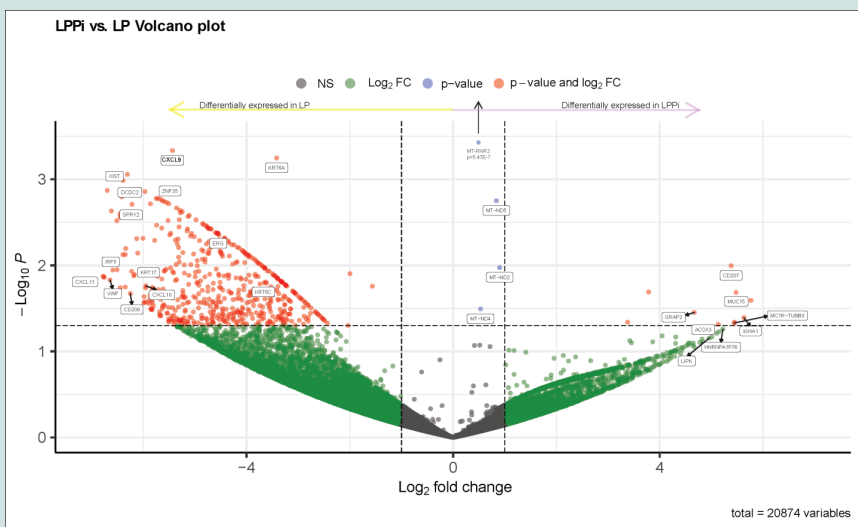
Transcriptome extraction was performed *in vivo* using 12 DBPs on three subjects; two with LPPi and one with LP [17]. In total, the experiment included 5 patches applied to LPPi lesions, 2 applied to LP



**Figure 1:** Clinical and histopathological studies of the LPPi and LP subjects. A. LPPi axilla lesions in Subject #1. B. LPPi groin lesions in Subject #2. C. LPPi lesional biopsy from Subject #2. Note the vacuolar degeneration of the epidermal basal cell layer, band-like lichenoid or perivascular lymphocytic infiltrates in the papillary dermis as well as superficial pigmentary incontinence and melanophages. (20X magnification). D. LP lesions on the right lower extremity. E. LP lesional biopsy. Note the hyperkeratosis, acanthosis, the sawtooth epidermal appearance, and the band-like dermal lymphohistiocytic infiltrate (10X magnification).



**Figure 2:** Heat map of differentially expressed genes with markers grouped by unsupervised hierarchical clustering. Unit variance is by row; blue color indicates lower mean expression and red color indicates higher mean expression. Columns are non-lesional skin (NLS), Lichen Planus Pigmentosus lesional skin (LPPi), and Lichen Planus lesional skin (LP). Fold changes for lesional (LS) vs NLS as well as LPPi vs LP. \*P < 0.05; \*\*P < 0.01; \*\*\* P < 0.001.



**Figure 3:** Volcano plot of differentially expressed genes in LP and LPPi. Red dots indicate the 543 genes that have a p < 0.05, only 15 of these were preferentially expressed in LPPi. Grey dots indicate genes with a less than 1-fold change.

lesions, and 5 more to adjacent non-lesional skin (NLS). Supplemental Figures S1-3 detail the placement of devices for the three subjects. Next-generation sequencing produced relative gene expression levels for approximately 12-13,000 mRNA transcripts/sample. First, lesional skin (LS) - comprised of pooled LPPi and LP expression data was compared to NLS to investigate common patterns of expression consistent with a lichenoid tissue reaction or interface dermatitis [6], the common histopathology of LP and LPPi. Next, differential gene expression between LPPi and LP was investigated to determine what distinguishes one from the other and if those distinctions correlate with their clinical presentations. Finally, gene set enrichment analysis (GSEA) and gProfiler were used to examine biological and molecular pathways involved in LPPi, LP, and their combined profile (LS).

#### Pathway analysis overview in LS vs NLS skin and LPPi vs LP

LS vs NLS differential gene expression analysis revealed 1506 upregulated genes and 17 downregulated genes ( $p < 0.01$ ). gProfiler [18,19] was used for pathway analysis along with the Gene Ontology (Ashburner et al. 2000; The Gene Ontology Consortium 2019) biological process database. Pathway analysis (ordered query,  $FDR < 0.01$ ) showed significant enrichment of pathways involving T-cell migration/activation, antigen processing, and presentation, myeloid leukocyte proliferation/migration, type I/II interferon signaling, programmed cell death, sequestering of metal ions, positive regulation of ERK1/ERK2 cascade, and cell-cell adhesions. There is significant downregulation of oxidative phosphorylation/cellular respiration pathways. The downregulated gene set is largely composed of mitochondrial transcripts that code for components of the electron transport chain (Figure 2 and Supplementary Table S1).

As denoted in the volcano plot in Figure 3, LPPi vs LP gene expression analysis produced 543 differentially expressed genes ( $p < 0.05$ ) - only 15 of which were preferentially expressed in LPPi; LP, the prototypical lichenoid skin reaction, seems to be far more active as an inflammatory process. Differentially upregulated genes in LP showed enrichment of GO biological processes such as cornification, hemidesmosome assembly, and cytokine secretion involved with an immune response (GO molecular function database singles out CXCR3 ligands as a highly enriched pathway). LPPi fails to show any meaningful pathway enrichment; however, its gene expression profile yields interesting insights into this poorly understood interfacedermatosis. Further details as to genes differentially regulated between LS vs NLS and LP vs LPPi are found in Supplementary Tables S1 and S2.

#### Upregulated Genes in LPPi vs LP

**Possible Acylceramide synthesis dysregulation in LPPi:** Both ELOVL4 and ALOX12b are involved in forming the corneocyte lipid envelope (CLE), an essential barrier defense and water retention mechanism of the skin [20]. Specifically, these enzymes contribute to the EOS class of ceramides, so named for their structure: ester- $\omega$ -hydroxy ultra-long chain (ULC) fatty acid and sphingosine. Inherited mutations in these genes, result in ichthyosis [21]. ELOVL4 is essential for ULC fatty acid synthesis and the resultant molecule undergoes enzymatic ceramide addition as well as esterification with linoleic acid before packaging in the lamellar granule. After exocytosis of the lamellar body, Alox12b oxidizes the linoleic acid moiety of the [EOS] CER molecule covalently bonding it to cellular components.

This structural bridge between cell and lipid components is crucial for the function of the CLE [22,23]. Antisense RNA for ALOX12b is a novel transcript with unknown functionality that is significantly upregulated in LPPi vs LP. Endogenously produced antisense RNA has been shown to regulate its coding gene function at the level of transcription and translation and has been seen in numerous human studies [24,25]. ALOX12b is upregulated in LP and LPPi vs NLS ( $\log_{2}FC = 4.4$  and  $p < 0.05$ ). Significant upregulation of antisense ALOX12b and ELOVL4 in LPPi vs LP ( $\log_{2}FC = 5.5, 4.0$  and  $p = 0.02, 0.06$  respectively) suggests that dysregulated [EOS] CER synthesis plays an important role in LPPi's pathogenesis; especially those components not shared with LP (i.e., T-cell activation and myeloid leukocyte maturation). Dysregulation of the CLE may result in the orthokeratosis noted on histology and contribute to the generally atrophic appearance of LPPi.

#### MC1R-TUBB3 (AC092143.1); LogFC of 5.4 in LPPi vs LP

MC1R is the melanocortin receptor 1, a 5 pass G-protein coupled receptor, that is important in regulating melanin production and thus skin/hair color in all mammals [26]. Classically, MC1R is stimulated by alpha melanocyte stimulating hormone ( $\alpha$ -MSH) which activates at least two pathways intracellularly: 1) one which raises intracellular cAMP and 2) another which works through mitogen associated protein kinase and is not dependent on elevated cAMP. The MC1R gene can be alternatively spliced at a polyadenylation site that allows for chimeric protein production with TUBB3, as they are adjacent to one another on chromosome 16 [27,28]. Moreover, UV radiation and other forms of overstimulation of the melanocortin receptor via  $\alpha$ -MSH have been found to switch MC1R transcript production over to MC1R-TUBB3; this change may fine-tune the melanocyte response to UV light over the medium to long-term [29]. MC1R-TUBB3 chimeric protein still binds  $\alpha$ -MSH but fails to raise cAMP secondary to intracellular changes in tertiary protein structure. Chimeric gene and protein production may be an adaptive long-term response to overstimulation of MC1R - which results in maintaining certain intracellular pathways (like MAPK noted above) while mitigating cAMP dependent pathways [27]. The upregulation of this chimeric gene may be either causing the pigmentation changes noted in LPPi or is downstream of the overstimulation of melanocytes that have already occurred secondary to the Koebner Phenomenon or some other cause, yet undiscovered.

#### GRAP2/GADS expression significantly upregulated in LPPi vs LP; 4-fold increase in expression

GRAP2 (GRB2-related adapter protein 2) is essential in T cells for release of immunomodulatory cytokines IL2 and IFN- $\gamma$  but does not play an essential role in T-cell binding or adhesion. It allows for influx of  $Ca^{2+}$  ions which mediates the release of cytokines. It is essential for thymic development and T cell survival and proliferation [29,30]. Additionally, GRAP2 can assist with T cell activation of MAPK's, JUN, and ERK1/ERK2 [31]. It is one of only a handful of upregulated genes in LPPi relative to LP and the regulatory effect of GRAP2/GADS may have some role in moderating the cytotoxic T cell effects on host tissues.

#### Activator of Exocytosis - Synaptotagmin like 1 (SYTL1) - upregulated in LPPi vs LP

The SYTL1 gene (also referred to as JFC1, SLP1, Exophilin-7)

plays a crucial role in exocytosis of secretory granules in melanocytes, neutrophils, and cytotoxic T- lymphocytes through interactions with RAB27A, MYO5a, and Melanophilin. RAB27A along with MYO5A are well known melanosome transport proteins because of their genetic affiliation with Griscelli syndrome, a rare recessive hypopigmentation disorder of the skin and hair with abnormal melanosome accumulation [32,33]. RAB27A is upregulated in LS vs NLS (logFC > 4 and p=0.02) but key effector molecule SYTL1 is uniquely upregulated in LPPi (logFC = 5.5, p=0.075) vs LP. Further investigation would be necessary to determine the cell types expressing SYTL1 in LPPi. Melanocytes are usually not considered a factor in lichenoid tissue reaction but they also express SYTL1 for melanosome trafficking and exocytosis.

To check for upregulation of genes associated with pigmentation and melanocytes we compared LPPi's gene expression to the Go:Ontology melanosome database. Of the 138 melanosome related genes, 34 were upregulated in LPPi including dopachrometautomerase, which is one of two genes responsible for the rate limiting step in melanin production (along with tyrosinase which was undetected in the data). Microphthalmia associated transcription factor (MITF) is responsible for upregulating the genes involved in melanin synthesis and it proved to be downregulated in LPPi relative to LP. Confoundingly, a majority of melanosome markers were actually upregulated in LP as opposed to LPPi. This could possibly reflect LPPi's clinical course, with intense inflammation and pigmentation coming early and then subsiding slowly. Or it may serve as a reminder of the complexity of pigmentation pathways and how they are often tied to inflammation in profound and poorly understood ways that beg more questions than answers.

Other genes upregulated in LPPi over LP include CD207 which is discussed in the following section, ACOX3, and MUC15. Peroxisomal enzyme ACOX3 is active on 2-methyl-branched-chain acyl-CoAs, very long chain fatty acids, and pristanoyl-Co [34]. Most tissues show some expression of this gene but no translation into functional protein. However, some human prostate cell lines produce functional ACOX3 protein [34]; representing a new metabolic pathway that could also be present in LPPi. MUC15 is a cell surface mucin which is expressed classically on apical epithelial tissue. It has also been found in bovine milk, as a product of ductal epithelial tissue [35]. It is also induced in the nasal epithelial during influenza infections; after the peak of cytokine/chemokine signaling when EGFR and phosphorylated ERK had reached its apex [36]. It has also been demonstrated that this cell surface bound mucin has an intracellular domain with motifs for regulating ERK1/2 signaling pathways in an EGFR like manner [37]. This poorly understood mucin may also be contributing to the ERK/RAS pathway dysregulation seen in LPPi.

### Genes Differentially Regulated in LP vs LPPi

**Langerin (CD207) is upregulated in LPPi; DC-SIGN (CD209) is upregulated in LP:** The integumentary system's dendritic cells serve as the crucial interface between innate and adaptive immunity. Tasked with phagocytosing foreign antigens and then presenting them to lymphocytes, Langerhans Cells (LCs - CD207+) and dermal dendritic cells (DDCs - CD209+) express C-type lectin proteins that function as pattern recognition receptors (PRRs) for pathogens and microbes as well as the nucleic acids that code for their foreign proteins. LCs resides in the suprabasal layer of the epidermis; DDC's usually are

found in the underlying dermis. CD207, a relatively specific marker of LC, is upregulated in LPPi by a fold change (logFC) greater than 5 relative to LP. Conversely, CD209 is upregulated in LP and is a marker of DDCs (p<0.05). This may be an artifact of only having one LP subject, however, a number of other dendritic cell markers common to both DDCs and LCs show relative upregulation in LS vs NLS [*i.e.*, CD1c, CD1b, CD1e, and CD205(LY75)]. Interestingly, LC specific markers have been noted in LPPi previously, as Kashima and colleagues (Kashima et al. 2007) found CD1a+ LCs in the epidermis and upper dermis of two LPPi patients in a case report using immunohistochemistry.

The natural progression of CD207+ and CD209+ antigen-presenting cells (APCs) is to proceed through a physiologic maturation process which includes detachment from surrounding cells and extracellular matrix (ECM), migration to lymph nodes, and alteration of gene expression profiles to detach, migrate and stimulate target leukocytes (namely CD8+ T<sub>effector</sub> cells)[38]. Colony stimulating factor 1 and its receptor (CSF1 and CSF1R) along with tumor necrosis factor alpha and its type 2 receptor [TNF $\alpha$  and TNFR2 (TNFRSF1B)] are upregulated in LS vs NLS and are essential for proper maturation of dendritic cells. Matrix metalloproteinase 2 and 9 (MMP2, MMP9) have increased expression in LS vs NLS and have been demonstrated to play a role in dendritic cell detachment from surrounding ECM and keratinocytes[38]. Likewise, IL32, which is upregulated 7 fold in LS vs NLS, is secreted by keratinocytes and promotes detachment and activation of LCs from keratinocytes prior to migration[40]. Finally, LCs and DDCs must change their chemokine/chemokine receptor profiles to home in on local lymph nodes rather than skin. CCR7 and CXCR4 are specific chemokine receptors that target afferent lymph nodes and endothelial venules for the migration of dendritic cells, and both are elevated in LS relative to NLS. Ultimately, the activated APCs express CD83[40]- effectively a maturation marker - and again we see significant upregulation in both LS subtypes vs NLS controls. Included in the highly enriched pathway 'myeloid leukocyte proliferation/migration' are significantly upregulated genes in LS vs NLS including myeloid cell nuclear differentiation antigen (MNDA), transmembrane immune signaling adaptor (TYROBP), leukocyte specific antigen (LST1), and protein kinase CAMP-dependent type 1 regulatory subunit alpha (PRKAR1A).

**CXCR3 upregulated in LS; LP has greater increase in CXCR3 ligands than LPPi:** CXCR3 (IP-10 receptor) expression has been noted in CD8+ T lymphocytes in oral and cutaneous lichen planus and may be an essential component to lichenoid skin reactions. LPPi and LP lesions in our experiment both showed significant upregulation of this receptor and two of its ligands, CXCL9, and CXCL10 when compared to NLS. RANTES (regulated on activation, normal T-cell expressed and secreted or CCL5) is also acutely upregulated in LS vs NLS; CCL5 attracts myeloid and effector T cells to the site of inflammation as well as maintains T resident memory cells. When comparing LPPi to LP, however, LP showed significantly greater expression of CXCL9, 10, and 11 (logFCs of 5.4, 6.7, and 5.9, respectively), the three primary ligands of CXCR3. Pathway analysis using gProfiler and the GO molecular function database identified CXCR3 (FDR<0.05) chemokine receptor binding as the top pathway for the LP expression profile.

### **Genes involved in T-cell development and activation is upregulated in LPPi& LP**

Lichenoid skin reactions, or interface dermatosis, are known for their band-like lymphocytic infiltrate comprised of activated CD8+ and CD4+ T-cells that attack the basal layer of the dermal/epidermal junction (Sontheimer 2009). Consistent with this model, LS showed significant upregulation of markers for T-cell activation (CD2 [41] and regulation of cytotoxic response (CD6 [42]). Transcription factors important to T cell development (RUNX1, RUNX3, and FOXP3) were also significantly upregulated ( $p < 0.01$ ) in both diseases. Observed Foxp3 expression in LPP that was more comparable to control healthy skin than an inflammatory condition like LP. However, this study finds Foxp3 expression in LPPi upregulated vs NLS and statistically equivalent to LP's expression level. Included in the GO ontology T-cell selection pathway is SLAMF6, DOCK2, IRF4, CD3G, ZMIZ1, LY9, JAK3, IRF4, ITK, CD74, RHOH, TOX, ZAP70, and XBP1, all of which showed significantly increased expression in LS vs NLS.

### **Interferon inducible proteins upregulated in LS - IRF5 uniquely elevated in LP**

Interferon regulatory factor 5 (IRF5) is one of a family of transcription factors that signals downstream of PRRs along with co-stimulation of interferon alpha (IFN $\alpha$ ) and interferon beta (IFN $\beta$ ). IRF's can be activated via infection, by genetic predisposition, and through de novo mutations [42]. In LP, IRF5 is upregulated 4.4-fold compared to LPPi ( $p < 0.05$ ). IRF5 expression typically promotes TNF- $\alpha$  and thus could be in part responsible for the increased cytokine production in LP vs LPPi thus contributing to its more aggressive basal keratinocyte injury. Interferon alpha inducible proteins 27/6 (IFI27, IFI6), interferon regulatory factors 1/4/8 (IRF1/4/8) interferon induced proteins with tetratricopeptide repeats 2/3 (IFIT2/3), interferon induced transmembrane protein 1 (IFITM1), major histocompatibility complex class I E/C/F (HLA-E/C/F), and 11 other genes induced by IFN $\alpha$  and IFN $\beta$  are all upregulated in LPPi and LP vs NLS (PTPN6, GBP2, UBE2K, MYD88, EGR1, OAS1, SETD, BST2, IFNAR2, ISG20, IKBKE). The innate immune response driven by type one and two interferons is likely important for the cytokine profile and T cell inflammatory process seen in ILDs.

### **Keratin 6/16/17, hallmarks of psoriasis and wound healing, are upregulated in LP**

In normal wound healing of the epidermis a variety of alarmins are released by keratinocytes: TNF $\alpha$ , S100 calcium-binding proteins, and a unique set of keratin intermediate filaments (KRT6/16/17) [43]. This set of keratin genes induce superficial keratinocytes to behave more like basal counterparts, by maintaining active nuclei and retaining their ability to grow and divide. This is an evolutionarily beneficial response following injury as it promotes keratinocytes proximal to damaged skin to forego terminal differentiation and fill in the gap of lost tissue thus achieving hemostasis and returned barrier integrity. Specifically, KRT6 increases cell-cell and cell-ECM adhesions providing increased mechanical integrity while decreasing migration and directionality. Meanwhile, KRT17 increases the proliferative potential and also serves as a source of autoimmune amplification (i.e. psoriasis) [45].

Intermediate filaments KRT6a, 6b, 6c, and KRT17 expression levels are significantly higher in LP than in LPPi (logFC > 3 and  $P < 0.05$ ).

These findings could explain the raised papular nature of LP lesions as compared to LPPi lesions, which are macular to atrophic. This finding might also explain why the granular layer of the epidermis seems to expand in LP - Keratin6/17 expression is driving the production of more granular proteins and pushing more superficial keratinocytes to continue protein production and increase keratohyalin granules indicative of the granular layer.

Additionally, gProfiler analysis of LP's expression profile (using Reactome database [46]) showed cornified envelope and hemidesmosome assembly to be the two most upregulated pathways, both of which are consistent with alarmin KRT changes noted above. Some genes upregulated in the hemidesmosome pathway of LP are LAMC2 (Laminin subunit 2), DST (dystonin), and COL17A1 (collagen 17a1). Cornification pathways were significantly enriched as well and included Peptidase inhibitor 3 (PI3), small proline rich protein 2g and 1b (SPRR2G, SPRR2b - which crosslink envelope protein of keratinocytes) and the aforementioned KRT alarmin genes.

### **S100 proteins - antimicrobial and Ca++ binding activity**

Psoriasis and Calgranulin A/B (S100A7, A8, and A9) showed significantly increased expression levels (fold change (FC) greater than 6 and  $p < 0.01$ ) in LS vs NLS; they code for calcium-binding proteins that have antimicrobial properties. Aside from combatting specific microbes, they are also highly expressed in other inflammatory conditions of the skin like wound healing and autoimmune mediated dermatitis. S100B is also upregulated in LS vs NLS ( $p < 0.01$ ) and is classically a marker of neural ectoderm. This includes neural crest derivatives including melanocytes, Langerhans cells, dendritic cells, Merkel cells, and Schwann cells encasing nerves in the deeper dermal tissues [47]. Elevated S100B expression has also been reported in the serum of psoriasis patients.

## **Discussion**

Transcriptional profiling of skin diseases has provided important insights into their pathogenesis. Yet these types of studies necessitate skin biopsies and are thus invasive. We describe in this pilot study the use of anovel minimally invasive technology to provide transcriptional analysis of skin lesions. The target for this study is the rare disorder LPPi which is thought of as a variant of LPP. Both LPPi and LPP are ILDs or lichenoid tissue reactions and thus share nomenclature and taxonomy with LP. These groupings are coming under increasing scrutiny. It should be noted a recent report using qRT-PCR and immunohistochemistry described distinct differences between LPP and LP. These included IL-17A, IL-22, IL-23, Wnt5a, IFN-gamma, and FOXP3 which were elevated in LP in comparison to LPP. The present study cannot confirm the presence of many of the Th17 related signaling molecules in LP or LPPi as they were not detected in high enough quantities to be measured. Only IL22 was seen in LP and LPPi and while its expression was roughly 2.6-fold greater in LP than in LPPi, the difference was not statistically significant. The same is true of IFN-gamma, Wnt5a, and Foxp3 as each was upregulated in LP vs LPPi on average (logFC of 2.9, 2.8, and 0.9 respectively) but the difference between the two lesion subtypes was not significantly different. In the instance of Foxp3, LPPi and LP together were upregulated vs NLS (logFC = 6.4 and  $p < 0.001$ ). While Th17 immunologic pathways seem to play a diminutive role in LPPi, the overall expression profile in this study suggests a prominent role

for T-regulatory cell involvement and more broadly T cell activation and recruitment through interferon related signaling; albeit a slightly less robust role than in LP itself. While this study lacks power due to its exploratory nature and small sample size, preliminary findings suggest that LPPi might indeed represent a different disorder than LPP as compared to LP based on findings in this study and those from Kumuran, et al. Follow up studies are necessary to confirm discrete molecular and expression details for LPPi that were found here, to examine if these are consistently seen in LPPi vs LP. Other transcriptomic studies on ILDs more broadly implicate TNF and interferon signaling in the presence of keratinocytes as the primary components related to interface dermatitis. Both LP and LPPi show direct evidence of TNF alpha expression and strong indirect evidence of interferon signaling in their gene expression profiles, hinting at a common type 1 immunologic response. Gene expression profiling and other research on mucocutaneous LP point to CXCR3 expression and its ligands (*i.e.* CXCL9 and 10) as evidence of T cell recruitment and activation which is essential to the disease process of LP. This study shows LP following a pattern of gene expression highly comparable to earlier studies on LP; LPPi portrays a diminished yet still prominent role for CXCR3, CXCL9, and 10 as well as other related signaling molecules in its pattern of expression vs NLS.

Many reports emphasize the importance of T-cells in the pathogenesis of LP and other ILDs, but this study also demonstrates an important role for dendritic cells in the pathogenesis of LP and LPPi. One case study of LPPi demonstrated findings of abundant Langerhans Cells in the epidermis and superficial dermis via CD1a immunohistochemistry (Kashima, et al. 2007a) [48]. The elevated levels of CD207 in LPPi from this study seem to confirm an important role for these resident macrophages in the disease process. A more thorough characterization of melanophages might help clarify what markers of differentiation they express and their hematopoietic origins as they are one of the most prominent findings on histology and remain poorly characterized in the literature.

Though LP and LPPi share many transcriptional features, there are many differences (Figure 3) that could explain the distinctions between these clinical entities. The presence of keratins associated with hyperproliferation selectively in LP may explain the epidermal thickness and potentially the isomorphic phenomenon. In LPPi, the increased expression of MCR1-TUBB3 (the melanocortin receptor 1/ tubulin beta class III hybrid) which is known to be expressed after excessive UVR/ $\alpha$ -MSA stimulation of MC1R, is of particular interest. It could provide an explanation for the enhanced pigmentation found in this disorder or a post-hyperpigmentation “exhausted” melanocyte status [49,50]. Additionally, dysregulation of enzymes (antisense RNA to Alox12b and ELOVL4) involved in the synthesis of the CLE might be responsible for atrophic epidermis seen in LPPi and the orthokeratosis of the cornified cell layer noted on histology. Of interest, several studies on mucocutaneous Lichen Planus have noticed dysregulation of keratinocyte differentiation markers, like Alox12b, as important to the disease process [51-55].

A limitation of this study is the small number of subjects. However, the use of multiple samples from each subject increased the rigor of these studies. The advantage of this minimally invasive approach is the ease in obtaining multiple samples, in contrast to more invasive strategies such as skin biopsies [56-58]. It should be noted that recent

studies using this exact technology on both normal skin and lesional psoriasis lesions compared favorably to skin biopsies.

This pilot study describes a novel instrument that could have multiple uses in advancing cutaneous pathobiology. For example, the DBP could have use in providing a more comprehensive transcriptional snapshot of skin disorders. It may have diagnostic utility as well, by providing a measure of clinical improvement. Given that a major need in clinical dermatology, especially in psoriasis treatment, is to provide a basis for the use of a particular therapeutic, future studies could be designed to use this methodology pre-treatment, identifying biomarkers that therapy can target, and then comparing therapeutic outcomes to treatments chosen by other criteria.

## Acknowledgement

This research was supported in part by grants from the National Institutes of Health grant R01 HL062996 (JBT), Veteran's Administration Merit Awards 5I01BX000853 (JBT), 1101CX000809 (JBT), CX001019 (MJT), CX002141 (MJT). The content is solely the responsibility of the authors and does not necessarily represent the official views of the National Institutes of Health or the US Veterans Administration.

## References

1. Pock L, Jelínková L, Drlík L, Abrahámová S, Vojtechovská Š, et al. (2001) Lichen planus pigmentosus-inversus. J Eur Acad Dermatol Venereol 15: 452-454.
2. Aldahmesh MA, Mohamed JY, Alkuraya HS, Verma IC, Puri RD, et al. (2011) Recessive mutations in ELOVL4 cause ichthyosis, intellectual disability, and spastic quadriplegia. Am J Hum Genet 89: 745-750.
3. Nurmohamed S, Hardin J, Haber RM (2018) Lichen planus pigmentosus inversus in children: Case report and updated review of the literature. Pediatr Dermatol 35: e49-51.
4. Kanwar AJ, Dogra S, Handa S, Parsad D, Radotra BD (2003) A study of 124 Indian patients with lichen planus pigmentosus. Clin Exp Dermatol 28: 481-485.
5. Pinkus H (1973) Lichenoid Tissue Reactions: A Speculative Review of the Clinical Spectrum of Epidermal Basal Cell Damage With Special Reference to Erythema Dyschromicum Perstans. Arch Dermatol 107: 840-846.
6. Sontheimer RD (2009) Lichenoid Tissue Reaction/Interface Dermatitis: Clinical and Histological Perspectives. J Invest Dermatol 129: 1088-1099.
7. Lauffer F, Jargosch M, Krause L, Garzorz-Stark N, Franz R, et al. (2018) Type I Immune Response Induces Keratinocyte Necroptosis and Is Associated with Interface Dermatitis. J Invest Dermatol 138: 1785-1794.
8. Iijima W, Ohtani H, Nakayama T, Sugawara Y, Sato E, et al. (2003) Infiltrating CD8+ T Cells in Oral Lichen Planus Predominantly Express CCR5 and CXCR3 and Carry Respective Chemokine Ligands RANTES/CCL5 and IP-10/CXCL10 in Their Cytolytic Granules: A Potential Self-Recruiting Mechanism. Am J Pathol 163: 261-268.
9. Wenzel J, Peters B, Zahn S, Birth M, Hofmann K, et al. (2008) Gene Expression Profiling of Lichen Planus Reflects CXCL9+-Mediated Inflammation and Distinguishes this Disease from Atopic Dermatitis and Psoriasis. J Invest Dermatol 128: 67-78.
10. Kumaran MS, Bishnoi A, Srivastava N, Tekumalla S, Vinay K, et al. (2019) Significant reduction in the expression of interleukins-17A, 22 and 23A, forkhead box p3 and interferon gamma delineates lichen planus pigmentosus from lichen planus. Arch Dermatol Res 311: 519-527.
11. Bhutani LK (1986) Ashy dermatosis or lichen planus pigmentosus: what is in a name? Arch Dermatol 122: 133-133.
12. Vega ME, Waxtein L, Arenas R, Hojyo T, Dominguez-Soto L (1992) Ashy dermatosis and lichen planus pigmentosus: a clinicopathologic study of 31 cases. Int J Dermatol 31: 90-94.

13. Gupta V, Sharma VK (2018) Ashy dermatosis, lichen planus pigmentosus and pigmented cosmetic dermatitis: are we splitting the hair? *Indian J Dermatol Venereol Leprol* 84: 470.
14. Kumarasinghe SPW, Pandya A, Chandran V, Rodrigues M, Dlova NC, et al. (2019) A global consensus statement on ashy dermatosis, erythema dyschromicum perstans, lichen planus pigmentosus, idiopathic eruptive macular pigmentation, and Riehl's melanosis. *Int J Dermatol* 58: 263-272.
15. Kateb B, Chiu K, Black KL, Yamamoto V, Khalsa B, et al. (2011) Nanoplatforms for constructing new approaches to cancer treatment, imaging, and drug delivery: what should be the policy? *Neuroimage*. *Neuroimage* 54: S106-124..
16. Saria S, Goldenberg A (2015) Subtyping: What It is and Its Role in Precision Medicine. *IEEE Intell Syst* 30: 70-75.
17. Ibrahim S, Taft B, Wang Y, Lee B-I, et al (2022) Minimally invasive skin transcriptome extraction using a dermal biomarker patch. *Dermatol. Ther.* in press.
18. Reimand J, Isserlin R, Voisin V, Kucera M, Tannus-Lopes C, et al. (2019) Pathway enrichment analysis and visualization of omics data using g:Profiler, GSEA, Cytoscape and EnrichmentMap. *Nat Protoc* 14: 482-517.
19. Raudvere U, Kolberg L, Kuzmin I, Arak T, Adler P, et al. (2019) g:Profiler: a web server for functional enrichment analysis and conversions of gene lists (2019 update). *Nucleic Acids Res* 47: 191-198.
20. Akiyama M (2017) Corneocyte lipid envelope (CLE), the key structure for skin barrier function and ichthyosis pathogenesis. *J Dermatol Sci* 88: 3-9.
21. Jobard F, Lefèvre C, Karaduman A, Blanchet-Bardon C, Emre S, et al. Lipoygenase-3 (ALOXE3) and 12 (R)-lipoygenase (ALOX12B) are mutated in non-bullous congenital ichthyosiform erythroderma (NCIE) linked to chromosome 17p13. 1. *Hum Mol Genet* 11: 107-113
22. Moran JL, Qiu H, Turbe-Doan A, Yun Y, Boeglin WE, Brash AR, et al. A Mouse Mutation in the 12R-Lipoygenase, Alox12b, Disrupts Formation of the Epidermal Permeability Barrier. *J Invest Dermatol* 127: 1893-1897.
23. Kihara A (2016) Synthesis and degradation pathways, functions, and pathology of ceramides and epidermal acylceramides. *Prog Lipid Res* 63: 50-69.
24. Qu X, Alsager S, Zhuo Y, Shan B (2019) HOX transcript antisense RNA (HOTAIR) in cancer. *Cancer Lett* 454: 90-97.
25. Harshe RP, Xie A, Vuerich M, Frank LA, Gromova B, et al. (2020) Endogenous antisense RNA curbs CD39 expression in Crohn's disease. *Nat Commun* 11: 1-14.
26. Kolesnichenko M (2012) The Role of the Polyadenylation Site of the Melanocortin 1 Receptor in Generating MC1R-TUBB3 Chimeras ; Attenuation of Torci Delays the Onset of Replicative and Ras-induced Cellular Senescence. *Scripps Res Inst, La Jolla, California*.
27. Herraiz C, Olivares C, Castejón-Griñán M, Abrisqueta M, Jiménez-Cervantes C, et al. (2015) Functional Characterization of MC1R-TUBB3 Intergenic Splice Variants of the Human Melanocortin 1 Receptor. *PLOS ONE* 10: 0144757.
28. Dalziel M, Kolesnichenko M, Neves RP das, Iborra F, Goding C, et al. (2011)  $\alpha$ -MSH regulates intergenic splicing of MC1R and TUBB3 in human melanocytes. *Nucleic Acids Res* 39: 2378.
29. Yankee TM, Yun TJ, Draves KE, Ganesh K, Bevan MJ, et al. (2004) The Gads (GrpL) Adaptor Protein Regulates T Cell Homeostasis. *J Immunol* 3: 1711-1720.
30. Bilal MY, Zhang EY, Dinkel B, Hardy D, Yankee TM, et al. (2015) GADS is Required for TCR-Mediated Calcium Influx and Cytokine Release, but not Cellular Adhesion, in Human T Cells. *Cell Signal* 27: 841-850.
31. Kim J-E, White FM (2006) Quantitative Analysis of Phosphotyrosine Signaling Networks Triggered by CD3 and CD28 Costimulation in Jurkat Cells. *J Immunol* 176: 2833-2843.
32. Pfeffer SR (2001) Rab GTPases: specifying and deciphering organelle identity and function. *Trends Cell Biol* 11: 487-491.
33. Zerial M, McBride H (2001) Rab proteins as membrane organizers. *Nat Rev Mol Cell Biol* 2: 107-117.
34. Zha S, Ferdinandusse S, Hicks JL, Denis S, Dunn TA, et al. (2005) Peroxisomal branched chain fatty acid  $\beta$ -oxidation pathway is upregulated in prostate cancer. *The Prostate* 63: 316-323.
35. Pallesen LT, Pedersen LRL, Petersen TE, Rasmussen JT (2007) Characterization of carbohydrate structures of bovine MUC15 and distribution of the mucin in bovine milk. *J Dairy Sci* 90: 3143-3152.
36. Chen Y, Xue L, Guo D, Mao J, Wu M, et al. (2019) Combination Therapy of Acitretin Capsule and Chinese Herbs for Patients with Lichen Planus Pigmentosus-Inversus. *Chin J Integr Med* 25: 922-925.
37. Huang J, Che M-I, Huang Y-T, Shyu M-K, Huang Y-M, et al. (2009) Overexpression of MUC15 activates extracellular signal-regulated kinase 1/2 and promotes the oncogenic potential of human colon cancer cells. *Carcinogenesis* 30: 1452-1458.
38. Toebak MJ, Gibbs S, Bruynzeel DP, Scheper RJ, Rustemeyer T (2009) Dendritic cells: biology of the skin. *Contact Dermatitis* 60: 2-20.
39. Khawar MB, Abbasi MH, Sheikh N (2016) IL-32: A Novel Pluripotent Inflammatory Interleukin, towards Gastric Inflammation, Gastric Cancer, and Chronic Rhino Sinusitis. *Mediators Inflamm* 2016: 8413768.
40. Li Z, Ju X, Silveira PA, Abadir E, Hsu W-H, Hart DNJ, et al. CD83: Activation Marker for Antigen Presenting Cells and Its Therapeutic Potential. *Front Immunol* 10: 1312.
41. Vallejo AN, Brandes JC, Weyand CM, Goronzy JJ (1999) Modulation of CD28 Expression: Distinct Regulatory Pathways During Activation and Replicative Senescence. *J Immunol* 162: 6572-6579.
42. Gonçalves CM, Henriques SN, Santos RF, Carmo AM (2018) CD6, a Rheostat-Type Signalosome That Tunes T Cell Activation. *Front Immunol* 9: 2994.
43. Honda K, Takaoka A, Taniguchi T (2006) Type I Interferon Gene Induction by the Interferon Regulatory Factor Family of Transcription Factors. *Immunity* 25: 349-360.
44. Zhang X, Yin M, Zhang L-J (2019) Keratin 6, 16 and 17-Critical Barrier Alarmin Molecules in Skin Wounds and Psoriasis. *Cells* 8: 807.
45. Langbein L, Rogers MA, Praetzel S, Winter H, Schweizer J (2003) K6irs1, K6irs2, K6irs3, and K6irs4 represent the inner-root-sheath-specific type II epithelial keratins of the human hair follicle. *J Invest Dermatol* 120: 512-522.
46. Jassal B, Matthews L, Viteri G, Gong C, Lorente P, et al. (2020) The reactome pathway knowledgebase. *Nucleic Acids Res* 48: D498-503.
47. Salem SAM, El-Khateeb EA, Harvy M, Emam HME-S, Abdelaal W, et al. (2017) Study of serum levels and skin expression of S100B protein in psoriasis. *An Bras Dermatol* 92: 323-328.
48. Kashima A, Tajiri A, Yamashita A, Asada Y, Setoyama M (2007) Two Japanese cases of lichen planus pigmentosus-inversus. *Int J Dermatol* 46: 740-742.
49. Danielsson K, Coates P, Ebrahimi M, Nylander E, Wahlin Y, et al. (2014) Genes Involved in Epithelial Differentiation and Development are Differentially Expressed in Oral and Genital Lichen Planus Epithelium Compared to Normal Epithelium. *Acta Derm Venereol* 94: 526-530.
50. Gouveia-Figueira S, Danielsson K, Fowler C (2019) Changes in Proportions of Linoleic Acid-derived Oxylipins in Oral Lichen Planus. *Acta Derm Venereol* 99: 1051-1052.
51. Ashburner M, Ball CA, Blake JA, Botstein D, Butler H, et al. (2000) Gene ontology: tool for the unification of biology. *The Gene Ontology Consortium*. *Nat Genet* 25: 25-29.
52. Binder C, Cvetkovski F, Sellberg F, Berg S, Paternina Visbal H, et al. (2020) CD2 Immunobiology. *Front Immunol* 11: 1090.
53. Chen ZG, Wang ZN, Yan Y, Liu J, He TT, et al. (2019) Upregulation of cell-surface mucin MUC15 in human nasal epithelial cells upon influenza A virus infection. *BMC Infect Dis* 19: 622.

ISSN: 2373-1044

54. Gangoso L, Grande JM, Ducrest A-L, Figuerola J, Bortolotti GR, et al. (2011) MC1R-dependent, melanin-based colour polymorphism is associated with cell-mediated response in the Eleonora's falcon. *J Evol Biol* 24: 2055-2063.
55. The Gene Ontology Consortium (2019) The Gene Ontology Resource: 20 years and still GOing strong. *Nucleic Acids Res* 47: D330-338.
56. LeBoit PE (1993) Interface Dermatitis: How Specific Are Its Histopathologic Features? *Arch Dermatol* 129: 1324-1328.
57. Mohamed M, Korbi M, Hammedi F, Youssef M, Soua Y, et al. (2016) Lichen planus pigmentosus inversus: a series of 10 Tunisian patients. *Int J Dermatol* 55: 1088-1091.
58. Newton Y, Sedgewick AJ, Cisneros L, Golovato J, Johnson M, et al. (2020) Large scale, robust, and accurate whole transcriptome profiling from clinical formalin-fixed paraffin-embedded samples. *Sci Rep* 10: 17597.